Anogenital (Non-venereal) Diseases 73

Susan M. Cooper

Chapter Contents

Lichen Sclerosus 1255
Lichen Planus 1258
Zoon Balanitis/Vulvitis 1259
Epithelial Disorders of the Anogenital Region 1260
Red Scrotum Syndrome/Red Vulva Syndrome 1261
Premalignant and Malignant Lesions 1262
Dysesthetic Genital Pain Syndromes 1265
Benign Lesions 1267
The Anogenital Region and Systemic Disease 1268
Infections 1268
Erosive Genital Disease 1269

INTRODUCTION

The diagnosis and management of skin diseases in the anogenital region may be complex. The juxtaposition of urinary, genital, and alimentary tracts gives rise to special considerations at this site (Fig. 73.1), and disease of any of these major systems may present with cutaneous manifestations. A number of systemic diseases such as Crohn disease and zinc deficiency preferentially affect the anogenital area. Local factors, including warmth, moisture, irritants, friction, and the effects of body fluids, are important in this region, contributing to skin problems.

Skin conditions may be more difficult to diagnose in the anogenital region than at other cutaneous sites, as the typical appearance of a particular skin disease may be lacking and there may be a hesitation to perform biopsies. Examination of the scalp, nails, mouth, and extragenital skin frequently assists in diagnosis. Special considerations apply to treatment, as the natural occlusion of this area may increase the percutaneous absorption of topical corticosteroids, with the potential for cutaneous atrophy and/or hypothalamic–pituitary–adrenal axis suppression. Warmth and moisture increase the risk of bacterial and yeast infections.

Only a limited number of symptoms in the anogenital area are possible, and pruritus and genital pain may be the presenting feature of a wide variety of diseases.

LICHEN SCLEROSUS

Synonyms: ■ Lichen sclerosus et atrophicus ■ Balanitis xerotica obliterans (men) ■ Kraurosis vulvae (women)

Key features

- Chronic inflammatory disease with a predilection for the anogenital region
- Pruritus is the most frequent symptom
- Major clinical signs are pallor, atrophy, fissures, and foci of hyperkeratosis
- Scarring may cause loss of the normal architecture of the vulva in women and phimosis in men

Introduction

Lichen sclerosus is a chronic inflammatory disease that preferentially affects the anogenital region, although any cutaneous site may be affected; 15%–20% of patients with genital lichen sclerosus will have extragenital disease. Symptoms may be longstanding as there is frequently a delay in diagnosis. Patients require long-term evaluation due to the risk of scarring and the risk of developing squamous cell carcinoma (SCC)[1].

Epidemiology

Lichen sclerosus is 6–10 times more prevalent in women than in men. The disorder may occur at any age, but the two peaks of onset are childhood and after menopause (or in the 4th or 5th decade in men). Although most studies have centered on White European patients, there are reports of lichen sclerosus occurring in Africans and Asians. Powell et al.[2] calculated a prevalence of 1 in 660 women and an annual incidence of 52/100 000 in postmenopausal women. The incidence of lichen sclerosus in boys may be underestimated; when foreskins of circumcised boys were examined, 14% were found to have the characteristic features of lichen sclerosus[3].

Etiology

The cause of lichen sclerosus is unknown. In women, there is evidence to support an association with autoimmunity and heritability. Autoantibodies to extracellular matrix protein 1 (ECM1) are found in the majority of women with lichen sclerosus, but their role in pathogenesis is uncertain. A heritable risk is suggested by the occurrence of familial cases, as well as an association with HLA-DRB1*12 (and the related haplotype DRB1*12/DQB1*0301/04/09/010)[4] and autoimmune disorders such as thyroid disease[5]. However, in male patients, familial cases are uncommon, and HLA and autoimmune associations are rarely observed[6].

An infectious etiology has been proposed, but *Borrelia* or other spirochetal infection has not been confirmed in large studies. Local friction or rubbing may induce lesions of lichen sclerosus via the Koebner phenomenon, and some cases of early-onset lichen sclerosus may be associated with the antiandrogenic oral contraceptive pill. In men, chronic exposure of susceptible epithelium to urine due to naviculomeatal dysfunction (microurinary incontinence) has been proposed as causative[7]. Of note, lichen sclerosus of the penis does not occur in men circumcised at birth[6]. Whether urinary dysfunction plays a role in women and children is not known.

Clinical features

Both male and female patients may present with pruritus or soreness, but rarely are entirely asymptomatic[1,8]. Dyspareunia is frequently reported. Children with lichen sclerosus are more likely to present with urinary or bowel symptoms (e.g. constipation), purpura, or even hemorrhagic bullae, which may lead to a misdiagnosis of child abuse[8].

In women and girls, the characteristic clinical findings are vulvar hypopigmentation and thin, wrinkled, atrophic skin in a figure-of-eight distribution encircling the vulvar and perianal region (Fig. 73.2). Focal areas of hyperkeratosis, erosions, and fissures are frequently seen, with the perineum a common location for fissures. Additional cutaneous features that are helpful in identification are purpura (Fig. 73.3), telangiectasias, and rarely, hemorrhagic bullae. The hemorrhagic component can occasionally be so pronounced that it mimics a vascular lesion. Because lichen sclerosus is a scarring disease, architectural change is common (Fig. 73.4). Burying of the clitoris secondary to midline fusion or fusion of the labia minora to the labia majora may occur. In untreated or severe disease, there may be total loss of the labia minora

Downloaded for Anonymous User (n/a) at Egyptian Knowledge Bank from ClinicalKey.com by Elsevier on March 10, 2024. For personal use only. No other uses without permission. Copyright ©2024. Elsevier Inc. All rights reserved.

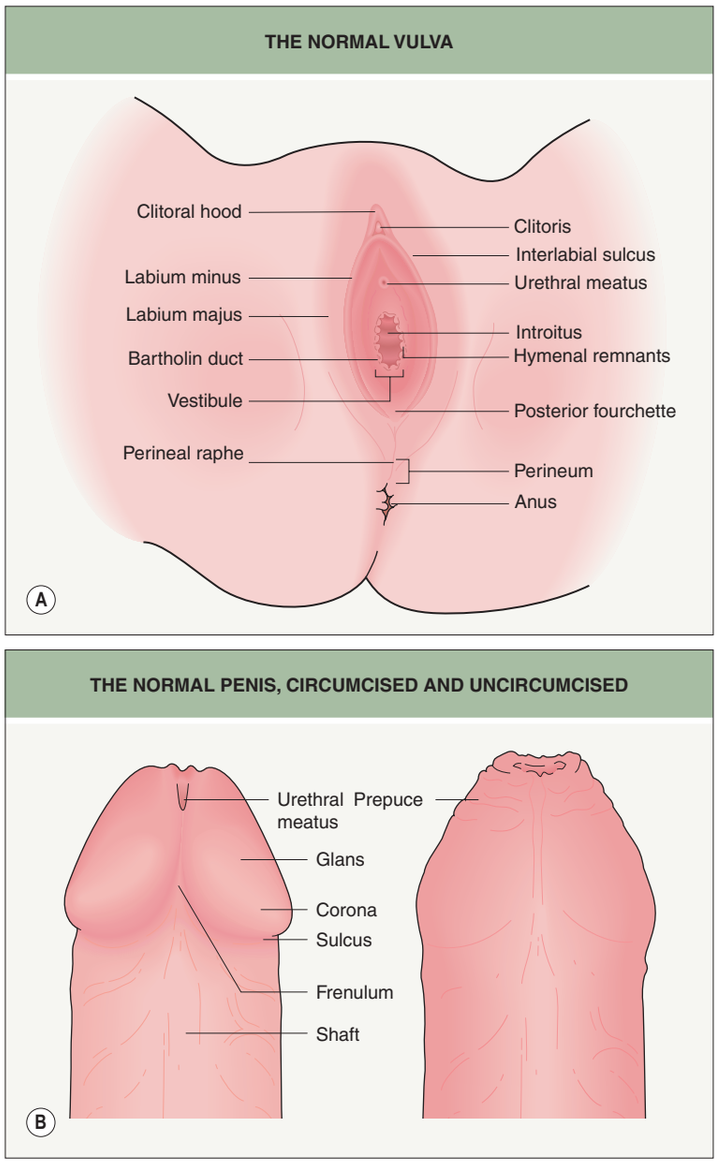

Fig. 73.1 Genital anatomy. A The normal vulva. **B** The normal penis, circumcised and uncircumcised.

Fig. 73.2 Anogenital lichen sclerosus in a girl. Hypopigmented, shiny skin in a figure-of-eight configuration with purpura, multiple erosions, and foci of hyperkeratosis. *Courtesy Julie V. Schaffer, MD.*

Fig. 73.3 Lichen sclerosus of the vulva with characteristic purpura. *Courtesy Kalman Watsky, MD.*

Fig. 73.4 Lichen sclerosus of the vulva. There is marked architectural change with loss of the labia minora and marked midline fusion.

and narrowing of the introitus. Darkly pigmented lentigines with an irregular outline may arise within areas of involvement.

Lichen sclerosus affects the glans penis and foreskin of men and, in contrast to women, involvement of the perianal region is uncommon. The disease usually presents with pruritus, pain, and dyspareunia[9]. Affected boys may have recurrent balanitis and a poor urinary stream, and circumcision is sometimes required. Men may report painful erections or erectile dysfunction as well as dysuria and spraying, dribbling, or poor flow of urine. Clinically, gray–white discoloration, purpura, and scarring can be seen (Fig. 73.5), leading to phimosis, paraphimosis, or constrictive posthitis. Additional architectural changes include coronal adhesions, reduced coronal sulcus and rim, and narrowing of the urethral meatus.

Extragenital lichen sclerosus favors the submammary region, as well as the shoulders, neck, and wrists, presenting as asymptomatic, hypopigmented, wrinkled patches with follicular plugging (see Ch. 44); occasionally, there are multiple guttate lesions. The diagnosis is established by a combination of the characteristic clinical and histologic findings.

Downloaded for Anonymous User (n/a) at Egyptian Knowledge Bank from ClinicalKey.com by Elsevier on March 10, 2024. For personal use only. No other uses without permission. Copyright ©2024. Elsevier Inc. All rights reserved.

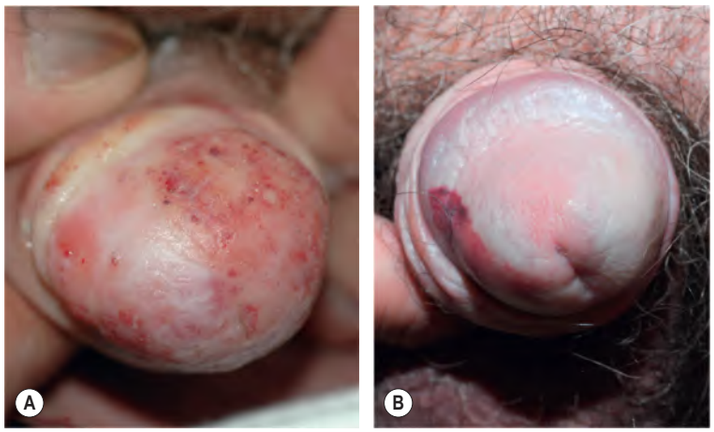

Fig. 73.5 Lichen sclerosus of the penis. A Erythematous and white plaque on the glans. **B** Shiny hypopigmented plaques of the glans in addition to purpura.
A, Courtesy Luis Requena, MD; B, Courtesy Kalman Watsky, MD.

Pathology

The principal histologic findings are compact orthokeratosis, follicular plugging (in non-mucosal sites), a thinned epidermis, vacuolization of the basal layer, and hyalinization of the papillary dermis. A dense band-like lymphocytic infiltrate is often observed. Squamous hyperplasia may be present and may be associated with an increased risk of SCC. In bullous lichen sclerosus, there is extensive vacuolar degeneration of the basal layer with clefting and hemorrhage. Early on, the papillary dermis may be edematous and homogenous, but, with time, hyalinization and sclerosis are observed.

Histologic examination of the skin is recommended as it can be difficult to distinguish lichen sclerosus from mucous membrane (cicatricial) pemphigoid or erosive lichen planus on the basis of clinical appearance alone. Occasionally, despite marked clinical changes, the disease cannot be confirmed histologically and repeat biopsies over time may be needed to establish the diagnosis. Of note, in genital lesions, a dense band-like lymphoid infiltrate with several intraepithelial lymphocytes may be the only histopathologic finding, with hyalinization of the superficial collagen absent or only present focally. In lesions that have been treated with potent topical corticosteroids, ascertaining the diagnosis histologically may also prove challenging.

Differential diagnosis

Very mild or early disease may be confused with dermatitis. The presence of genital scarring necessitates the exclusion of other scarring disorders such as erosive lichen planus and mucous membrane pemphigoid. The absence of oral or vaginal mucosal involvement helps to distinguish lichen sclerosus from erosive lichen planus. In children, sexual abuse must be considered, as lichen sclerosus and sexual abuse are not mutually exclusive. Associated pruritus and topical therapies can lead to superimposed lichen simplex chronicus as well as allergic or irritant contact dermatitis. Histologically, the presence of a dense lymphoid infiltrate may be misdiagnosed as mycosis fungoides; the latter diagnosis, especially in the genital region, requires compelling evidence, particularly in children.

Treatment

The main aim of therapy is to bring the disease under control as quickly as possible with the fewest side effects. For induction treatment (after the diagnosis is established), a superpotent topical corticosteroid such as clobetasol propionate 0.05% ointment is prescribed until signs and symptoms improve, typically 1 to 3 months[1,9–13]. This alleviates symptoms in the majority of patients, often within weeks. Subsequently, the corticosteroid is tapered over 2–3 weeks and clinical remission maintained by limited (typically twice weekly) application of a higher potency corticosteroid or daily application of a lower potency topical corticosteroid. In some women, there is complete resolution of signs as well as symptoms, with the exception of scarring, which is irreversible[8]. Beyond preserving clinical remission, maintenance therapy has been associated with a reduced occurrence of SCC[12].

In the management of vulvar lichen sclerosus without secondary SCC, there is no longer a role for vulvectomy. For longstanding disease in which narrowing of the introitus has resulted in dyspareunia, surgical refashioning with division of adhesions may be helpful. Vaginal dilators may also be needed, in addition to psychosexual counseling to address the psychological distress that frequently accompanies lichen sclerosus.

In male patients, first-line therapy consists of potent topical corticosteroids, with cotton swab/bud application for meatal involvement[9]. Those with urinary symptoms should be evaluated by a urologist. If treatment does not lead to improvement or a tight phimosis is present, circumcision is often necessary.

Longitudinal evaluation is essential for patients with lichen sclerosus because both men and women are at increased risk of developing genital SCCs (estimates of the risk are 2%–6%)[9,11,12]. Women with childhood-onset lichen sclerosus may be particularly at risk of developing genital SCC, and notably the myth that childhood lichen sclerosus resolves at puberty has been debunked[14]. Women with lichen sclerosus may develop *differentiated* vulvar intraepithelial neoplasia (VIN), which has a higher risk of developing into invasive SCC when compared to high-grade squamous intraepithelial lesion (HSIL); the latter is an HPV-associated disease and was previously known as undifferentiated VIN. Men are at risk of penile intraepithelial neoplasia. Non-healing fissures, ulcers, or nodules must be examined histologically. Written educational material and patient support groups are very helpful. It is essential that patients who notice any features of malignancy seek prompt medical assessment.

The first- and second-line therapies for anogenital lichen sclerosus are outlined in Table 73.1.

MANAGEMENT OF ANOGENITAL LICHEN SCLEROSUS ℞
General
• Soap substitutes and regular use of emollients* (e.g. white petrolatum) (3,2) • Apply white petrolatum prior to urinating, to minimize dysuria (2) • Silk or cotton underwear • Consider nighttime sedation, until pruritus controlled, to minimize scratching (3) • Estrogen replacement (topical or systemic [if not contraindicated]) for postmenopausal women with atrophic vulvovaginal disease (2) • Circumcision for phimosis or paraphimosis (2) • Regular (at least yearly) examination for SCC
First-line
Induction
• Superpotent (Class I) topical corticosteroid* (e.g. clobetasol 0.05% ointment) applied once to twice daily until signs and symptoms resolve (typically 1–3 months) (1), then taper to maintenance
Maintenance†
• Superpotent (Class I) topical corticosteroid* twice weekly at bedtime (1) – *OR* – • Potent (Class II, e.g. mometasone furoate 0.1% ointment) topical corticosteroid* twice weekly (1) – *OR* – • Midpotency (Class V) topical corticosteroid* daily (2) • Topical calcineurin inhibitors 2–3 times a week‡ (1)
Second-line
• Intralesional triamcinolone acetonide (e.g. 5–10 mg/cc monthly) (1) • Oral retinoids (e.g. acitretin 10–50 mg/day for >6 months) (1) • Methotrexate (2) • Hydroxychloroquine (3) • JAK inhibitors • UVA1 (50 J/cm^2) (1) • Photodynamic therapy (2) • Fractional CO_2 laser (especially for hyperkeratotic plaques) (3) • Circumcision, if unresponsive to medical treatment (3) • Surgery to correct narrowing of introitus and reverse clitoral burying (3)
*Ointments are preferred over creams because they are less irritating. †Ongoing maintenance, regardless of symptoms, has been shown to decrease the development of SCC. ‡Adding in tandem after topical corticosteroids rather than concurrently may reduce associated burning; some clinicians avoid chronic use because the long-term risk is unknown and there is an increased risk of secondary SCC in lichen sclerosus.

Table 73.1 Management of anogenital lichen sclerosus. Topical JAK inhibitors and dupilumab have been used for extragenital lichen sclerosus. Key to evidence-based support: (1) prospective controlled trial; (2) retrospective study or large case series; (3) small case series or individual case reports. SCC, squamous cell carcinoma.

Downloaded for Anonymous User (n/a) at Egyptian Knowledge Bank from ClinicalKey.com by Elsevier on March 10, 2024. For personal use only. No other uses without permission. Copyright ©2024. Elsevier Inc. All rights reserved.

LICHEN PLANUS

Synonyms: ■ Vulvovaginal gingival syndrome/vulvo-vaginal-gingival syndrome (erosive lichen planus in women) ■ Peno-gingival syndrome in men ■ Mucosal lichen planus

Key features

- Four distinct forms of genital lichen planus are observed: (1) papules or plaques in the setting of generalized cutaneous lichen planus; (2) erosive disease; (3) hypertrophic disease; and (4) lichen planopilaris
- Although cutaneous disease is often self-limiting, mucous membrane disease is more persistent
- The classic findings in cutaneous disease are violaceous, flat-topped papules and plaques; lacy white streaks typically occur on the genitalia as well as the oral mucosa
- Erosive lichen planus often involves multiple mucous membrane sites – in particular, the vulva, vagina, and oral mucosa

Introduction

Approximately 50% of women and 25% of men with cutaneous lichen planus have genital involvement. The classic violaceous papules and plaques typically affect the labia minora and majora or the mons pubis in women and the glans or shaft of the penis in men. Erosive lichen planus is a distinct subtype of the disease, characterized by severe, scarring erosive disease of the vestibule, introitus, vagina, and oral cavity[13,15]. Hypertrophic genital lichen planus and lichen planopilaris are the least frequent forms.

Epidemiology

Lichen planus is more common in women, generally presenting in the sixth decade. The exact prevalence is unknown, but it is likely that some cases of genital involvement in cutaneous lichen planus may be missed.

Etiology

Lichen planus probably represents T cell-mediated damage to epidermal cells that express altered self or foreign antigens on their surface, but the exact etiology is unknown (see Ch. 11). There is an autoimmune phenotype (see Lichen sclerosus above) in female patients with vulvar lichen planus and an association with autoimmune disease[5]. While some cases of lichen planus may be drug-induced, there are no definite associations with genital disease. Infectious triggers, particularly hepatitis C viral infection, may be associated with mucosal lichen planus in certain parts of the world such as the Mediterranean basin and Japan.

Clinical features

There are four distinct presentations of genital lichen planus[15,16], as follows:

- In *classic* lichen planus, the genital lesions are similar to those in other cutaneous sites, but lacy reticulation may be very prominent. Genital involvement is usually limited to the mons pubis and the labia majora and minora in women or the glans penis and shaft in men (see Fig. 11.4B). Penile plaques are frequently annular (Fig. 73.6A). Scarring is not a feature of classic lichen planus. Severe cutaneous pruritus is the usual presenting symptom, but genital lesions may be asymptomatic. Lesions are usually self-limited.
- *Erosive* lichen planus occurs much more frequently in women than in men. Pain and dyspareunia are the most common complaints. In female patients, extensive erosions occur around the vaginal orifice, edged by lacy white reticulations; similar lesions may also occur on the labia (Fig. 73.6B). Erosive lichen planus frequently leads to scarring, resulting in distortion of the vulvar architecture[13]. In severe cases, there may be complete obliteration of the vaginal canal and urinary retention. Vaginal involvement can present with a discharge, erythema and contact bleeding of the vaginal mucosa, and/or scarring with adhesions. Oral involvement is frequently observed, usually in the form of a desquamative gingivitis, but lacy white reticulations and erosions may also occur. Erosions limited to the perianal area alone have been described.
- In the *hypertrophic* form of lichen planus, hyperkeratotic white plaques on the vulva or shaft of the penis may be seen.
- In *lichen planopilaris*, follicular keratotic papules are limited to the hair-bearing labia majora and the mons pubis, but may also be seen on the scalp and trunk and in the axillae.

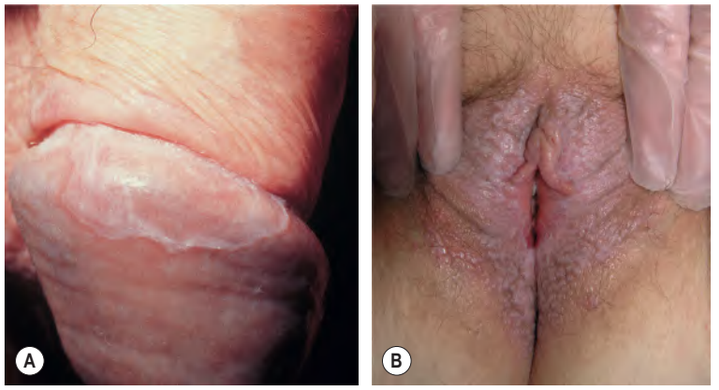

Fig. 73.6 Lichen planus. A An annular band is seen on the glans of the penis. This is a typical finding. **B** Erosive lichen planus of the vulva with fissures and an extensive white lacy pattern. *A, Courtesy R. Turner, MD.*

Pathology

The typical histologic findings are irregular epidermal acanthosis, accentuation of the granular layer, liquefactive degeneration of the basal layer, and a band-like dermal infiltrate of lymphocytes. It is more difficult to interpret biopsy specimens of mucous membranes, where these findings are more variable. Because there is loss of the epithelium in erosive disease, the specimen should include the edge of the erosion as well as the surrounding lacy reticulated skin. Despite this, it is sometimes difficult to unequivocally confirm the disease, but histologic evaluation can aid in excluding other disorders in the differential diagnosis.

Differential diagnosis

The principal entities in the differential diagnosis are lichen sclerosus; autoimmune bullous disease, including mucous membrane pemphigoid; Zoon (plasma cell) vulvitis; Behçet disease; graft-versus-host disease; and high-grade squamous intraepithelial lesion (HSIL; previously referred to as undifferentiated vulvar intraepithelial neoplasia) or SCC. Direct immunofluorescence may be necessary to exclude an autoimmune bullous disease. Orogenital ulceration raises the possibility of Behçet disease (see Ch. 26). For oral lesions, lupus erythematosus is in the differential diagnosis, but this would be unusual in the anogenital region. Early lichen planus may be confused with vulvar eczema and there may be superimposed lichen simplex chronicus. For hypertrophic disease, HSIL, SCC, and lichen simplex chronicus are the major entities in the differential diagnosis.

Treatment

The treatment of genital lichen planus is outlined in Table 73.2. Potent or moderately potent corticosteroid ointments will control most symptoms of classic genital lichen planus, as the disease is usually self-limiting. Hypertrophic disease may require intralesional corticosteroids.

The management of erosive lichen planus is more difficult, as the disease is often more persistent[15–17]. The majority of patients will respond to a 3-month course of topical clobetasol propionate 0.05% ointment (as described for lichen sclerosus) and thereafter can be maintained on moderately potent corticosteroids or twice weekly application of the potent corticosteroid. A combination of a moderately potent corticosteroid with a topical antifungal cream (e.g. econazole) may be as effective as more potent corticosteroids, particularly for maintenance therapy. For refractory disease, anecdotal case reports describe benefit from intralesional corticosteroid injections, topical calcineurin inhibitors, oral hydroxychloroquine, systemic immunosuppressants, and acitretin (see Table 73.2). Tricyclic antidepressants can be used to treat associated vulvodynia. Erosive vaginal disease requires

Downloaded for Anonymous User (n/a) at Egyptian Knowledge Bank from ClinicalKey.com by Elsevier on March 10, 2024. For personal use only. No other uses without permission. Copyright ©2024. Elsevier Inc. All rights reserved.

MANAGEMENT OF ANOGENITAL LICHEN PLANUS
General
• Soap substitutes and regular use of emollients* (e.g. white petrolatum) (3) • Apply white petrolatum prior to urinating, to minimize dysuria (3) • Consider nighttime sedation, until pruritus controlled, to minimize scratching (3) • Estrogen replacement (topical or systemic [if not contraindicated]) for postmenopausal women with atrophic vulvovaginal disease (3)
First-line
Induction
• Superpotent (Class I) topical corticosteroid* (e.g. clobetasol 0.05% ointment) applied once to twice daily until signs (e.g. erosions) and symptoms resolve (1), then taper to maintenance • Intravaginal corticosteroids (*for vaginal disease*) nightly until controlled and then taper to maintenance (2); consider combining with weekly oral fluconazole (150–200 mg/week) for vulvovaginal candidiasis prophylaxis (3)
Maintenance
• Superpotent topical corticosteroid* (twice weekly) or combined moderately potent corticosteroid/antifungal/antibacterial preparations (3) • Intravaginal corticosteroids† (*for vaginal disease*) at bedtime, at minimum frequency needed for control ± weekly fluconazole (150–200 mg/week) for vulvovaginal candidiasis prophylaxis (3) • Regular use of vaginal dilators to prevent stenosis (3)
Second-line
• Topical calcineurin inhibitors (2) • Intralesional triamcinolone acetonide (e.g. 5–10 mg/cc monthly; hypertrophic disease, recalcitrant erosions) (3)
Recalcitrant or severe disease
• Prednisone (40–60 mg/day) – short course for rapid control and while initiating corticosteroid-sparing agent (2) • Hydroxychloroquine (2) • Systemic immunosuppressants (e.g. methotrexate (2), mycophenolate mofetil (2), azathioprine (3), TNF inhibitors (3)) • Acitretin (hypertrophic disease) (3) • Systemic antibiotics (tetracyclines ± nicotinamide) (3) • Photodynamic therapy (requires sedation) (1) • Surgery to correct narrowing of introitus and reverse clitoral burying in women or circumcision in men (3)
*Ointments are preferred over creams because they are less irritating. †Compounded vaginal suppositories that contain 200–300 mg of hydrocortisone acetate can be inserted nightly until control achieved, then frequency tapered.

Table 73.2 Management of anogenital lichen planus. Topical and oral JAK inhibitors as well as dupilumab have been used for extragenital lichen planus. Key to evidence-based support: (1) prospective controlled trial; (2) retrospective study or large case series; (3) small case series or individual case reports.

intravaginal corticosteroids and regular use of vaginal dilators to prevent stenosis; surgery to lyse adhesions may be required.

Long-term evaluation of these patients is advised because of the risk of developing SCC[18]; the incidence of the latter has been estimated to be ~2.4%[16]. For further details on the treatment of lichen planus, including systemic agents for severe, refractory disease, see Chapter 11.

ZOON BALANITIS/VULVITIS

Synonyms: ■ Plasma cell balanitis/vulvitis ■ Vulvitis/balanitis circumscripta plasmacellularis ■ Zoon's erythroplasia

Key features

- Male predominance
- Erythematous, moist, speckled, discrete thin plaques
- Involvement of adjacent surfaces produces "kissing" lesions in men
- In men, cured by circumcision

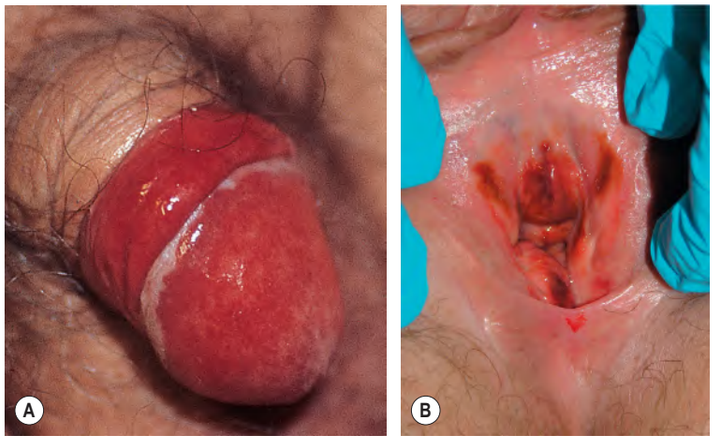

Fig. 73.7 Zoon balanitis and vulvitis. A There are moist red "kissing" lesions on adjacent surfaces of the glans and prepuce. **B** Light to dark red patches of the clitoris, vestibule, introitus, and labia.

Introduction

While most authorities believe this condition occurs in men, its existence as a separate entity in women has been questioned. This is because many of the clinical features in women are indistinguishable from those of erosive lichen planus, mucous membrane pemphigoid, or lupus erythematosus, and the lichenoid features histologically overlap with erosive lichen planus and lichen sclerosus.

Epidemiology

Zoon balanitis/vulvitis may occur at any age but is usually seen from the third decade onwards in uncircumcised men and in postmenopausal women.

Etiology

The etiology is unknown, but poor penile hygiene or chronic irritation from warmth or rubbing has been suggested. Zoon balanitis has not been observed in circumcised men. In women, the vulvitis may represent a reactive process secondary to trauma or reflect a postmenopausal hypoestrogenic state.

Clinical features

In men, the lesions on the glans penis may be asymptomatic or give rise to pruritus or dysuria. The lesions are erythematous, discrete, moist thin plaques with a "cayenne pepper" speckled appearance and a deep red to reddish-brown hue. "Kissing" lesions with involvement of adjacent, touching areas, e.g. around the urethral meatus, are a characteristic finding (Fig. 73.7A). Shallow erosions may resolve slowly, leaving a rusty color. In women, thin erythematous plaques similar to those in men may be seen anywhere on the vulva (Fig. 73.7B). Lesions may be asymptomatic or cause burning, dyspareunia, dysuria, pruritus, or pain.

Pathology

The typical histologic picture is a dense lichenoid infiltrate in the upper and mid dermis with a predominance of plasma cells. Additional features include "lozenge-shaped" keratinocytes, vascular proliferation, hemosiderin deposition, and erythrocyte extravasation.

Differential diagnosis

In order to establish the diagnosis, a biopsy is usually performed. The major disorder in the differential diagnosis is erosive lichen planus, but the possibility of cutaneous malignancy (e.g. SCC *in situ*, extramammary Paget disease) must be considered.

Treatment

In men, a circumcision will almost always cure the disease. Potent topical corticosteroids or topical calcineurin inhibitors may provide some symptomatic relief[19,20]. Vaginal estrogen may be helpful for some women.

Downloaded for Anonymous User (n/a) at Egyptian Knowledge Bank from ClinicalKey.com by Elsevier on March 10, 2024. For personal use only. No other uses without permission. Copyright ©2024. Elsevier Inc. All rights reserved.

EPITHELIAL DISORDERS OF THE ANOGENITAL REGION

Dermatitis

Key features

- Appearance ranges from mild erythema to marked lichenification
- Pruritus and soreness are the main complaints
- A mixed etiology is common
- Exogenous irritants and allergens must be sought

Introduction

Although anogenital dermatitis has traditionally been subdivided into endogenous dermatitis (e.g. seborrheic dermatitis, atopic dermatitis), lichen simplex chronicus, and exogenous dermatitis (e.g. allergic or irritant contact dermatitis), in practice it is often difficult to distinguish between subtypes. A mixed picture, in which endogenous dermatitis is worsened by exogenous irritants or allergens, is common. Lichen simplex chronicus may develop secondarily to other anogenital diseases such as candidiasis, psoriasis, and lichen sclerosus.

Pathogenesis

The majority of patients with vulvar dermatitis have an endogenous predisposition, having either an atopic background or seborrheic dermatitis. The anogenital area is susceptible to irritants, and allergic contact dermatitis is very prevalent in this site; the latter is usually due to topical medications or personal hygiene products. Psychological issues and local environmental problems such as heat, sweating, and over-cleansing may contribute.

Clinical features

The cutaneous features are varied, ranging from mild, usually poorly demarcated erythema to severe lichenification (Fig. 73.8). Symptoms include pruritus (Figs. 73.9 & 73.10), pain, and superficial dyspareunia in women. In lichen simplex chronicus, scratching or rubbing is associated with unremitting pruritus. Fissuring is common, especially perianally. The typical anogenital sites affected are the labia majora and the mons pubis in women, the crura and scrotum in men, and the perianal area in both sexes. Lichenification is most often seen on the scrotum in men and the labia majora in women. Signs of seborrheic dermatitis (e.g. a scaly scalp, greasy scaling and erythema of nasolabial folds and eyebrows), as well as erythema at other flexural sites such as the inframammary crease, intergluteal fold, and axilla, should be sought. Atopic dermatitis at other sites will usually be obvious from the history or examination. Any contribution from dermatographism can also been assessed.

Fig. 73.8 Vulvar dermatitis. Lichenification is prominent. The underlying diagnosis was atopic dermatitis.

Differential diagnosis

The key to making the diagnosis is a thorough dermatologic examination. The diagnosis is usually made on the basis of clinical appearance, but a skin biopsy can be helpful in excluding other diagnoses. For example, plaques of psoriasis are more well-circumscribed than those of dermatitis. Extramammary Paget disease should also be considered, but these lesions are also sharply demarcated and usually asymmetric. It is important to identify irritants and possible allergens through a careful history and possibly patch testing. In addition, bacterial and *Candida* cultures should be performed to exclude superimposed infection, which is common in the anogenital region. Early lesions of lichen sclerosus may be indistinguishable from dermatitis.

Treatment

The regular use of bland emollients and the substitution of an emollient for soap is recommended. Exacerbating factors, including stress, heat, excessive washing, use of premoistened personal hygiene wipes ("wet wipes"), and candidiasis, should be identified. A major therapeutic aim is reduction of pruritus and soreness. If the area is acutely inflamed, potent topical corticosteroids, often in combination with topical

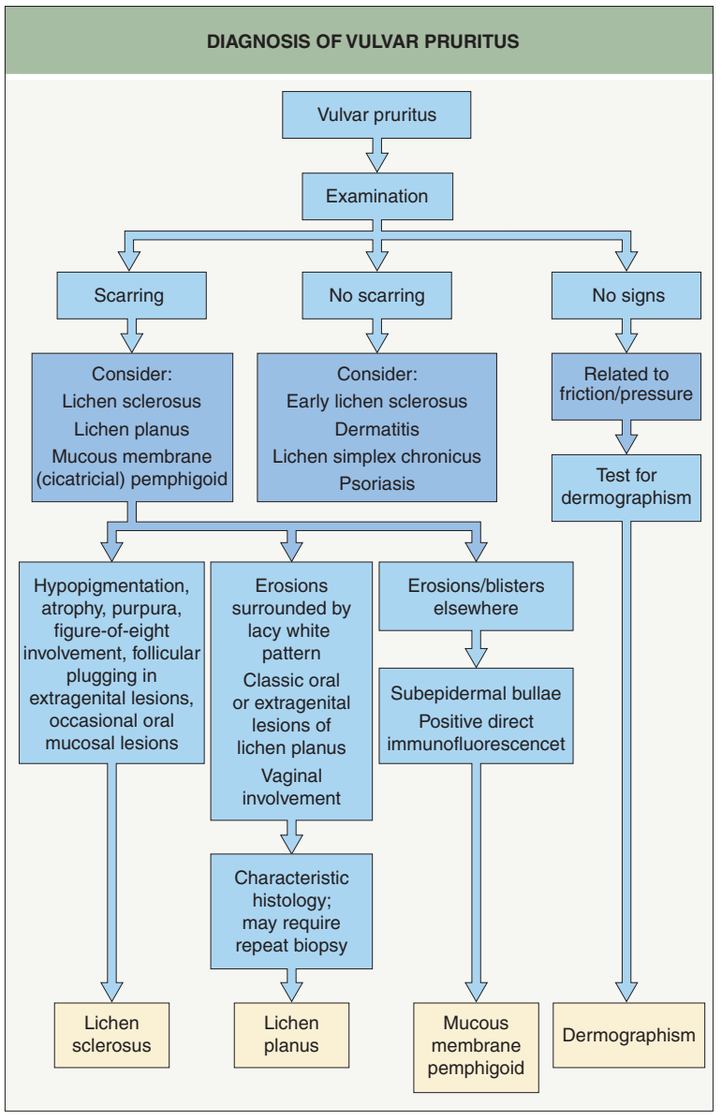

Fig. 73.9 Diagnosis of vulvar pruritus.

Downloaded for Anonymous User (n/a) at Egyptian Knowledge Bank from ClinicalKey.com by Elsevier on March 10, 2024. For personal use only. No other uses without permission. Copyright ©2024. Elsevier Inc. All rights reserved.

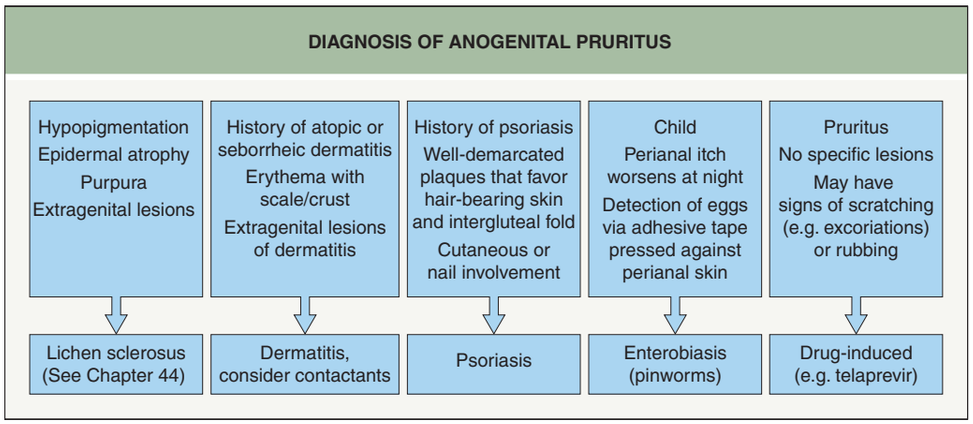

Fig. 73.10 Diagnosis of anogenital pruritus. Histologic evaluation may be required to confirm the clinical diagnosis (e.g. lichen sclerosus) or to exclude more unusual etiologies (e.g. extramammary Paget disease).

antifungal agents, topical antibacterial agents, and/or topical immunomodulators, are helpful. Over a period of a few weeks, the topical corticosteroid can be tapered to one that is less potent. When lichenification is present, it is especially important to break the itch–scratch cycle. Additional therapies include sedative antihistamines or tricyclic antidepressants, usually doxepin, at bedtime (see Ch. 6).

Contact Dermatitis

It is important to consider the possibility of contact dermatitis in any patient with dermatitis, a history of reactions to topical medications, or treatment-resistant disease. Contact dermatitis of the anogenital region may be irritant or allergic (see Chs. 14 & 15)[21]. Irritant contact dermatitis is seen in infants as diaper dermatitis and in older patients as a consequence of overzealous cleaning, urinary or fecal incontinence, or chronic diarrhea.

Allergic contact dermatitis is diagnosed by patch testing and can often arise as a treatment-related secondary condition. Topical medications are the most common cause of allergic contact dermatitis in the anogenital region[22]. Relevant allergens include preservatives, topical anesthetics, topical antibiotics, corticosteroids, fragrances, lanolin, and rubber chemicals. In perianal dermatitis, medications (topical, per anum), hemorrhoidal creams, and toilet wipes are common culprits. In addition to contact dermatitis, type I immediate hypersensitivity reactions to latex and seminal fluid may occur.

Psoriasis

Key features

- Erythematous well-defined plaques
- Evidence of psoriasis elsewhere on total body skin examination
- Intergluteal cleft frequently affected

Psoriasis of the anogenital region may appear quite different from psoriasis at other sites (see Ch. 8). The typical silvery scale is lost, as in other flexural sites such as the axillae and submammary region.

Clinical features

In women, erythematous, smooth, clearly demarcated plaques typically affect the labia majora and the mons pubis. Psoriasis is usually confined to the hair-bearing areas, so the labia minora are unaffected. Men may have circumscribed plaques on the glans penis and shaft of the penis (Fig. 73.11). Persistent, painful fissuring of the perianal area and the intergluteal cleft can be a severe problem in both sexes.

Differential diagnosis

Often the diagnosis is very straightforward, established from a combination of the clinical appearance in the genital region plus typical lesions elsewhere on the body or classic nail changes. Seborrheic dermatitis may be difficult to distinguish from psoriasis, and sometimes, clear features of both psoriasis and seborrheic dermatitis are seen in the same patient, where the term "sebopsoriasis" seems appropriate. The differential diagnosis includes tinea cruris (especially if there are pustules, an active border, extension of lesions onto the buttock or upper inner thigh, and/or concomitant tinea pedis or unguium), and erythrasma. In patients with reactive arthritis, lesions identical to those of psoriasis may be seen on the penis.

Fig. 73.11 Psoriasis of the penile shaft. Well-demarcated erythematous plaque with slight scale. Similar lesions can be seen in patients with reactive arthritis (formerly Reiter disease). *Courtesy Jean L. Bolognia, MD.*

Treatment

Unfortunately, topical therapy for anogenital psoriasis is not entirely satisfactory. Many topical agents suitable for use on the body, such as coal tar, anthralin, vitamin D derivatives, or retinoids, may be too irritating in flexural sites. Moderately potent topical corticosteroid–antibiotic–antifungal combinations remain the most useful therapy; however, in intertriginous sites, corticosteroid-induced atrophy remains a concern. Topical tacrolimus, pimecrolimus, or roflumilast may be helpful in such occluded sites. Some patients will improve when a systemic agent is used (e.g. methotrexate, cyclosporine, TNF inhibitors, systemic immunomodulators such as ixekizumab), usually for widespread disease.

RED SCROTUM SYNDROME/RED VULVA SYNDROME

The red scrotum syndrome (RSS) and red vulva syndrome (RVS) typically present in older individuals as persistent erythema of the scrotum or vulva with associated burning, pruritus, and/or pain. The precise etiology is unclear but possible contributing factors include rebound vasodilation resulting from prolonged use of topical corticosteroids and neurogenic inflammation[23]. Another theory is that it represents a form of localized erythromelalgia.

Downloaded for Anonymous User (n/a) at Egyptian Knowledge Bank from ClinicalKey.com by Elsevier on March 10, 2024. For personal use only. No other uses without permission. Copyright ©2024. Elsevier Inc. All rights reserved.

Because both RSS and RVS are diagnoses of exclusion, other entities including atopic, seborrheic or contact dermatitis, inverse psoriasis, superficial infections (e.g. tinea, candidiasis, erythrasma), fixed drug eruption, and extramammary Paget disease need to be considered. However, given the possible contribution of topical corticosteroids, RSS and RVS may be superimposed on another cutaneous disease. Treatment is challenging and includes the taper and then discontinuation of topical corticosteroids, thus attempting to avoid a rebound with more burning and erythema. This approach is similar to that employed in patients with steroid-induced rosacea. Based upon case reports, improvement has been observed with topical (e.g. timolol) and oral (carvedilol [6.25 mg three times weekly]) β-blockers[24], topical calcineurin inhibitors, oral doxycycline, and oral gabapentinoids (e.g. gabapentin, pregabalin).

PREMALIGNANT AND MALIGNANT LESIONS

Squamous Intraepithelial Neoplasia (Vulvar, Penile, Anal)

Synonyms: ■ Bowenoid papulosis ■ Bowen disease (squamous cell carcinoma *in situ*) ■ Erythroplasia of Queyrat

Key features

- High-grade squamous intraepithelial lesion (HSIL) of the vulva, previously known as usual type or undifferentiated vulvar intraepithelial neoplasia (uVIN), and most cases of PeIN (penile intraepithelial neoplasia), and AIN (anal intraepithelial neoplasia) are associated with human papillomaviruses
- Lichen sclerosus and lichen planus are predisposing factors for differentiated type VIN (dVIN)
- Despite treatment there is a high recurrence rate

Introduction

The term "squamous intraepithelial neoplasia" defines an intraepithelial change within anogenital epithelium that is premalignant. There have been several iterations of nomenclature but no universal agreement exists amongst all medical specialties. The International Society for the Study of Vulvovaginal Disease (ISSVD) divides vulvar squamous intraepithelial lesions (SIL) into: (1) high-grade squamous intraepithelial lesion (HSIL) – formerly referred to as usual type or undifferentiated vulvar intraepithelial neoplasia (uVIN); and (2) differentiated VIN (dVIN)[25]. The term for squamous intraepithelial neoplasia in men is penile intraepithelial neoplasia (PeIN), and for anal disease, anal intraepithelial neoplasia (AIN).

It is now recommended that the terms Bowen disease, erythroplasia of Queyrat, and Bowenoid papulosis not be used for lesions in the anogenital area. However, dermatologists still recognize a distinct clinical variant, Bowenoid papulosis, characterized by discrete papules in a younger age group and a tendency for spontaneous regression. Additionally, some authorities believe that erythroplasia of Queyrat and Bowen disease remain useful terms in men.

Epidemiology

It may occur at any age, but the incidence in young women is rising. Early evidence suggests that rates of HSIL may be falling in HPV-vaccinated populations.

Pathogenesis

Oncogenic human papillomaviruses, chiefly HPV types 16 and 18, are implicated in most cases of squamous intraepithelial neoplasia, especially HSIL, PeIN, and AIN. There is also an association with smoking and immunosuppression, including HIV infection. Lichen sclerosus and lichen planus are predisposing factors for dVIN.

Pathology

Intraepithelial neoplasia is characterized by nuclear hyperchromasia, disordered maturation of keratinocytes, and coarse nuclear chromatin. Multiple mitotic figures are usually visible above the basal layer.

Clinical features

The clinical presentation is varied. Erythematous well-demarcated plaques that look similar to plaques of Bowen disease in extragenital sites may occur on the vulva or the keratinized epithelium of the penis in men. Alternatively, warty white plaques, erosions, or hyperpigmented patches may be seen. Shiny erythematous plaques may occur on the glans and prepuce of the uncircumcised male (erythroplasia of Queyrat; Fig. 73.12). In patients with Bowenoid papulosis-type lesions, distinct red–brown papules are seen on the genitalia (Fig. 73.13A), which may extend to the inner thighs (Fig. 73.13B). Differentiated VIN usually presents as small ulcers or keratotic plaques.

Differential diagnosis

Intraepithelial neoplasia must be distinguished from inflammatory conditions such as lichen sclerosus, as well as condyloma acuminatum, Zoon balanitis/vulvitis, and cutaneous malignancies, in particular early invasive SCC.

Treatment

Treatment options depend on the site, the extent of disease, the age of the patient, and the type of intraepithelial neoplasia, but recurrence is a problem with all treatment modalities. In localized disease, a biopsy to establish the diagnosis, followed by local excision, is preferred, so long as the surgery is not too mutilating. In uncircumcised men, circumcision may reduce the risk of progression to invasion. Observation may be an option in selected cases if treatment is not feasible; however, if progression is observed, then surgical excision is necessary. Differentiated VIN associated with lichen sclerosus or lichen planus has a high risk of progression to invasive disease and must be excised. Cryosurgery is rarely indicated in the opinion of the author, as recurrence rates are very high; laser therapy also has a high recurrence rate. Topical imiquimod or fluorouracil may be helpful in some cases, especially when the disease is multifocal, although local side effects may limit their use. In some, but not all, patients, imiquimod

Fig. 73.12 Penile intraepithelial neoplasia. Persistent erythema not responding to topical corticosteroids. *Courtesy R. Turner, MD.*

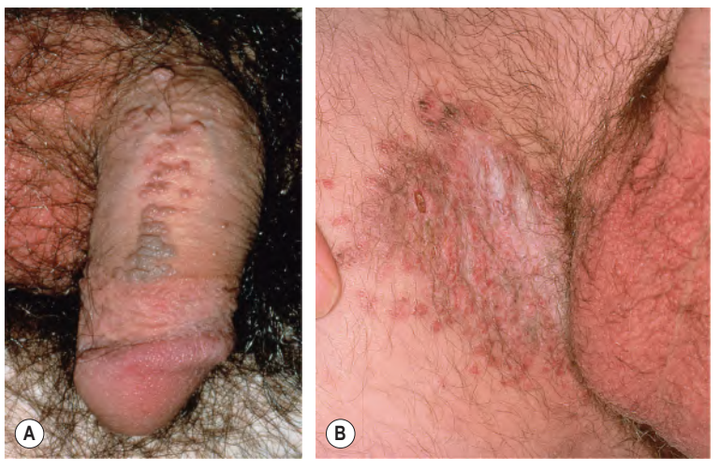

Fig. 73.13 Bowenoid papulosis variant of intraepithelial neoplasia. A Multiple red–brown to brown papules on the shaft of the penis. **B** Coalescence of red–brown to brown papules on the upper inner thigh. *B, Courtesy Robert Hartman, MD.*

Downloaded for Anonymous User (n/a) at Egyptian Knowledge Bank from ClinicalKey.com by Elsevier on March 10, 2024. For personal use only. No other uses without permission. Copyright ©2024. Elsevier Inc. All rights reserved.

can lead to histologic regression of disease and viral clearance[26,27]. In widespread disease, simple vulvectomy has been performed, but only after exhaustion of all other options.

Long-term evaluation is recommended and should include serial examinations and cervical and anal cytology, especially in the setting of HIV infection. Examination of sexual partners is advised.

Prevention

Vaccines are available to prevent infection with high-risk HPV subtypes (see Ch. 79). They are 97% effective in a population naive to these viruses at the time of the first vaccination. Cessation of cigarette smoking should be advised as this is a known risk factor for recurrence.

Pseudoepitheliomatous Keratotic and Micaceous Balanitis

This is a rare condition that occurs in elderly circumcised men[28]. Thick keratotic plaques develop on the glans penis. This condition may progress to verrucous carcinoma or SCC.

Invasive Squamous Cell Carcinomas

Key features

- Most common malignant tumor in the anogenital region
- Etiology is different from SCCs arising in actinically damaged skin

Epidemiology

Squamous cell carcinoma most frequently occurs in the elderly, although it may occur in young adults (see Ch. 108). The incidence of genital SCC in women is rising.

Pathogenesis

HPV infection and lichen sclerosus account for the majority of SCC of the anogenital region. HPV-associated tumors tend to arise in younger adults, while lichen sclerosus-related tumors occur in postmenopausal women and older men. Smoking and immunosuppression are also risk factors. SCC is very rare in circumcised men; the presence of a foreskin, which can lead to trapping of smegma and low-grade inflammation, may predispose to the development of carcinoma. SCC of the genital region is rarely due to cumulative UV light exposure, although there have been reports of SCC of the penis and scrotum in men who had received multiple PUVA treatments. Tar, chimney soot, asbestos, and petroleum products are known carcinogens in the case of scrotal SCC.

Clinical features

In men, the majority of lesions present as ulcers or plaques on the glans, the coronal sulcus, or the prepuce (Fig. 73.14). Ulcers often have a heaped-up edge. In the uncircumcised man, delay in diagnosis may occur because of associated phimosis masking the tumor. Although any area on the vulva may be involved, the labia are the most frequent sites. The clinical presentation varies from non-healing ulcers or fissures to nodules and plaques. Invasive anal carcinoma may arise from the anal margin or from within the lower anal canal.

Differential diagnosis

SCC must be distinguished from other tumors such as amelanotic melanoma or basal cell carcinoma. It is important to biopsy any suspicious lesion that develops in the anogenital region.

Treatment

Treatment is usually surgical, with the extent of surgery dependent on both the size and depth of invasion[29]. Microinvasive tumors (≤1 mm invasion and a maximum diameter of 2 cm) are removed via wide local excision. Sentinel lymph node biopsy is sometimes performed in patients with earlier stage SCC. For more advanced disease, inguinofemoral lymphadenectomy may be recommended. If the SCC arises within a background of lichen sclerosus, it is important to continue maintenance therapy with topical corticosteroids as this appears to reduce the recurrence rate of SCC[30].

Fig. 73.14 Invasive squamous cell carcinoma of the foreskin. This patient with psoriasis had received PUVA therapy without genital protection.

Anogenital Melanoma

Key features

- Rare tumor not related to UV exposure
- Delayed diagnosis is common resulting in greater depth of invasion
- Mucosal lentiginous melanoma is the most common histologic type
- Associated with a poor prognosis

Introduction

Although anogenital melanoma is a rare tumor, melanoma is the second most common primary malignant tumor of the vulva in women.

Epidemiology

Female genital tract melanomas account for <3% of melanomas diagnosed in women but ~20% of all mucosal melanomas[31]. Vulvar melanomas outnumber vaginal melanomas. Compared with cutaneous melanomas, vulvar and penile melanomas occur in an older population, typically in the seventh decade, although they may appear at any age. While the incidence of cutaneous melanoma is increasing, the incidence of urogenital tract melanoma in women is stable.

Pathogenesis

Melanoma is a multifactorial disease, but two of the major risk factors – sun exposure and melanocytic nevi – play a minimal (nevi) or no known (UV) role in anogenital melanoma. Current evidence suggests that the behavior of vulvar melanoma is similar to that of cutaneous melanoma and thus should be staged and initially managed in a similar manner. However, comparative genomic hybridization has shown a greater frequency of *KIT* mutations and fewer *BRAF* mutations in mucosal melanomas as compared to cutaneous melanomas (see Ch. 113)[32], and this does impact the choice of targeted therapy for metastatic disease. Tumor molecular profiling also includes other genes that have been detected in vulvovaginal melanomas (e.g. *NRAS*, *TP53*). Of note, 15% of patients with vulvar melanoma report a family history of cutaneous melanoma.

Clinical features

In women, melanomas may present with bleeding, pruritus, or a nodule. Amelanotic melanomas account for up to 10% of vulvovaginal melanomas. Tumors can arise throughout the genital tract, including the cervix and the vagina, as well as any site on the vulva. The labia minora, followed by the labia majora/clitoris, are the most common tumor sites. In men, a crusted nodule is the most frequent presentation, with most melanomas arising on the glans penis, although they may occur at any site, including the scrotum[33].

Because anogenital melanomas are often diagnosed at a more advanced stage, overall prognosis is significantly worse when compared

Downloaded for Anonymous User (n/a) at Egyptian Knowledge Bank from ClinicalKey.com by Elsevier on March 10, 2024. For personal use only. No other uses without permission. Copyright ©2024. Elsevier Inc. All rights reserved.

to more common cutaneous melanomas. Reported 5-year survival rates have varied from 5% to 25% for vulvovaginal melanomas, 10% for penile melanomas[31], and 5%–35% for anorectal melanomas[34]. Greater depth of invasion at the time of diagnosis may be due to a less noticeable location or the rich vascular and lymphatic network of the urogenital tract. Although these factors contribute to early spread and development of metastases, it remains to be determined whether anogenital melanomas are fundamentally more aggressive.

Pathology

On genital skin, mucosal lentiginous melanoma is the most frequent histologic type of melanoma. Nodular and superficial spreading melanomas occur less frequently. Mucosal lentiginous melanomas share some histologic features with cutaneous lentigo maligna melanomas. As with cutaneous melanoma, prognosis is determined by tumor thickness at presentation.

Differential diagnosis

For macular lesions, the major differential is mucosal melanosis. Palpable pigmented melanomas must be distinguished from atypical-appearing seborrheic keratoses, melanocytic nevi, or Bowenoid papulosis. Melanocytic nevi superimposed on lichen sclerosus may have an atypical clinical appearance and histopathologic features of a persistent nevus. Anorectal melanoma may initially be misdiagnosed as a hemorrhoid or adenomatous polyp.

Treatment

Due to the rarity of the tumor, there have been no randomized therapeutic trials. Vulvar and penile melanomas are staged and treated similarly to cutaneous melanoma. Surgical resection is the treatment of choice. Based upon recent consensus guidelines, the goal of surgical management of anogenital melanomas is to achieve microscopically clear (>1 mm) margins in the least radical fashion[34]. Lymphadenectomy is limited to clinically evident metastatic regional nodal disease, with sentinel lymph node biopsy recommended if it directs adjuvant treatment or clinical trial entry. Approximately one-third of patients have nodal disease at the time of presentation.

Immunotherapy (e.g. anti-CTLA-4 antibodies, anti-PD-1/PD-L1 antibodies) may improve survival rates and, depending upon the presence of specific mutations, targeted KIT or selective BRAF inhibitors may also be considered. Palliative radiotherapy has been tried for extensive local disease and can be considered in conjunction with immunotherapy.

Basal Cell Carcinoma

Basal cell carcinoma may occur in the anogenital area and is usually diagnosed clinically as SCC prior to biopsy or excision. Rarely, it has been reported to metastasize.

Genital Lymphoma

The anogenital region is a rare site of involvement for lymphoma. Several different types of lymphoma have been reported, including diffuse large B cell and other non-Hodgkin lymphomas. The usual presentation is that of a solid non-tender nodule. Plaques and tumors of mycosis fungoides (MF) can also be seen in this location, but MF *restricted* to the anogenital region should be seriously questioned and alternative diagnoses (e.g. pseudolymphomatous lichen sclerosus) considered.

Extramammary Paget Disease

Key features

- Rare intraepithelial adenocarcinoma
- May be primary (80%–90% of patients) or secondary to an underlying malignancy (10%–20% of patients)

Introduction

Extramammary Paget disease (EMPD) is a rare intraepithelial adenocarcinoma that develops primarily in apocrine-rich sites, with the vast majority arising in the anogenital region. Rarely EMPD occurs in the axillae or locations such as the eyelid, umbilicus, or external auditory canal. EMPD can either be *primary* (of cutaneous origin) or *secondary* (of non-cutaneous origin); the latter represents intraepithelial spread of neoplastic cells from an underlying internal malignancy. EMPD may become invasive and spread via the lymphatic system.

Epidemiology

Elderly White women most commonly develop this malignancy, but in Japan there is a male predominance.

Etiology and classification

The histogenesis of primary cutaneous EMPD has been long debated but appears in some patients to be of apocrine origin. Recurrent mutations in chromatin remodeling genes have recently been identified in both EMPD and mammary PD[35], along with the importance of the Msi1–mTOR pathway. Primary (type 1) EMPD can be divided into three subtypes: 1a – non-invasive; 1b – invasive; and 1c – associated with pagetoid spread from an underlying adnexal carcinoma. Secondary EMPD consists of either epidermotropic metastases or direct extension of a gastrointestinal tract (type 2) or urothelial tract (type 3) malignancy.

Clinical features

The vulva in women and the perianal region in men are the most commonly affected sites[36]. There may be associated pruritus or burning or the lesions may be asymptomatic. A slowly expanding, asymmetric erythematous plaque is typical, with a sharp demarcation between normal and involved skin (Fig. 73.15A–C). Scattered areas of white scale and erosion can give rise to a "strawberries and cream" appearance. Occasionally, lesions are pigmented.

Pathology

The diagnosis must be confirmed by histologic examination. Vacuolated pagetoid cells in the epidermis are distinctive (Fig. 73.15D), but immunohistochemical staining is necessary to exclude pagetoid melanoma and pagetoid Bowen disease, as well as to help differentiate between primary and secondary EMPD (Fig. 73.16)[37]. The diagnosis of primary EMPD requires a search for an underlying cutaneous adnexal carcinoma.

Differential diagnosis

EMPD is most often clinically misdiagnosed as psoriasis or dermatitis, leading to a delay in diagnosis. Histopathologically, the differential diagnosis consists primarily of melanoma and Bowen disease, but may include pagetoid dyskeratosis, clear cell papulosis, and Langerhans cell histiocytosis.

Evaluation

A thorough review of systems and complete physical examination, including lymph nodes, should be performed. Because the initial site of EMPD often correlates with the type of underlying malignancy, screening studies include the following: (1) perianal EMPD – upper and lower endoscopy +/– CT scan, cystoscopy, urine cytology, prostate-specific antigen (PSA, in men); (2) penoscrotal EMPD – colonoscopy, cystoscopy, PSA; and (3) vulvar EMPD – pelvic examination, Pap smear, colposcopy, cystoscopy, abdominal/pelvic CT scan. In women, breast examination and mammography are also recommended. Serum carcinoembryonic antigen (CEA) levels can be measured to monitor tumor status. Of note, the value of routine screening for primary intraepithelial (type 1a) EMPD has recently been questioned[38].

Treatment

It is important to distinguish between primary and secondary EMPD, and when possible determine if the malignancy is invasive (see Fig. 73.16). For localized disease in the anogenital region, wide local excision is usually performed. However, because of the multifocal nature of EMPD and the presence of clinically inapparent extension of disease, recurrences are very common. Mohs micrographic surgery often represents a preferred surgical option[37]. Additional treatment options include topical imiquimod, topical 5-fluorouracil, topical rapamycin, radiotherapy, photodynamic therapy, and CO_2 laser ablation, with

Downloaded for Anonymous User (n/a) at Egyptian Knowledge Bank from ClinicalKey.com by Elsevier on March 10, 2024. For personal use only. No other uses without permission. Copyright ©2024. Elsevier Inc. All rights reserved.

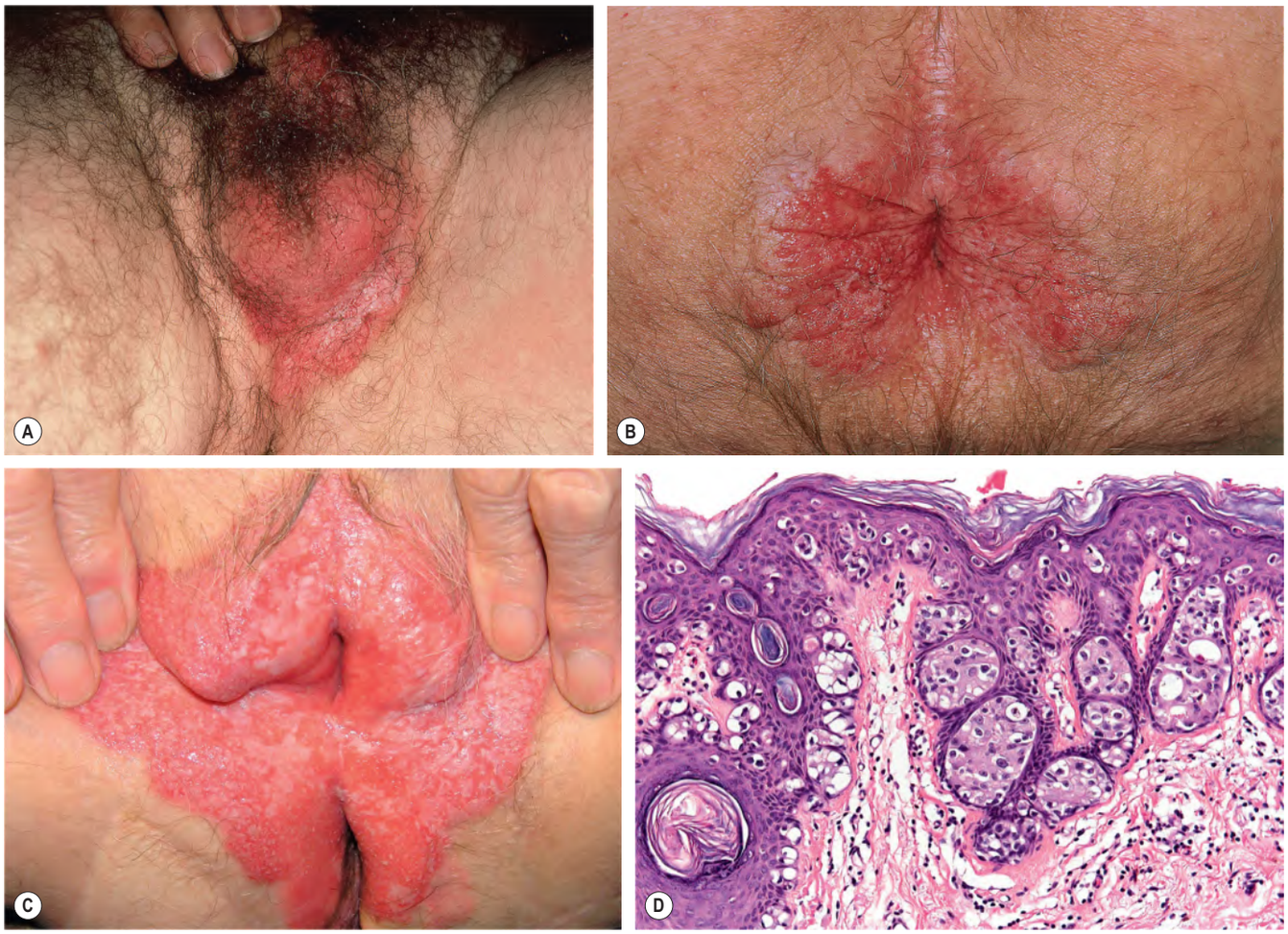

Fig. 73.15 Extramammary Paget disease. A Erythematous plaque with hydrated scale at the base of the scrotum. **B** Well-demarcated perianal plaque with both erosions and scale, giving rise to a "strawberries and cream" appearance. **C** Extensive, well-demarcated disease of the vulva with multiple foci of hydrated white scale. **D** Photomicrograph demonstrating pagetoid cells within the epidermis, both as single cells and in nests. *B, Courtesy Kalman Watsky, MD; D, Courtesy Lorenzo Cerroni, MD.*

combination therapy often employed. Long-term follow-up is recommended because invasive disease can occur.

DYSESTHETIC GENITAL PAIN SYNDROMES

The term "dysesthetic genital pain syndrome" encompasses a number of disorders in which the clinical appearance is normal despite the patient's experience of severe disabling pain (Fig. 73.17). Because these diagnoses require the absence of a clinically identifiable neurologic disorder (e.g. a radiculopathy), a neurologic examination is a prerequisite. Unmedullated C fibers transmit pain and touch, and it is now recognized that these nerve fibers can be remodeled after a stimulus has passed, explaining why perception of subsequent stimuli may be altered. Relatively minor inflammation or trauma, often unrecalled, may precipitate the onset of pain. The ISSVD has published a classification scheme for vulvar pain (Table 73.3)[39]. Of note, these pain disorders often have a profound effect on a patient's well-being and sexual functioning.

General Principles of Management

Simple measures, self-help, and patient education often lead to improvement. For more severe or long-standing symptoms, a multidisciplinary approach that includes physiotherapists, pain management specialists, psychologists, and psychosexual counselors is often required. The key interventions are patient education, pain modification (via local anesthetics, amitriptyline, gabapentinoids), physical therapy to address hypertonic pelvic floor muscles that can exacerbate pain, and psychological and psychosexual support[40].

Localized Vulvodynia (Vestibulodynia)

Key features

- Superficial dyspareunia
- Tenderness on localized pressure within the vulvar vestibule
- Occurs in young, sexually active women

Introduction

"Localized vulvodynia" is now the preferred term for this specific subtype of the vulvar pain syndrome, characterized by superficial dyspareunia and point tenderness within the vestibule, often at 5 and 7 o'clock.

Clinical features

This particular localized pain syndrome occurs in the young, premenopausal, sexually active woman whose main complaint is one of dyspareunia on penetration. Insertion of tampons may be impossible. The vulva looks entirely normal but there is pain when the vestibular area is pressed by a cotton-tipped applicator.

Differential diagnosis

Localized vulvodynia must be differentiated from other causes of vulvar pain (see Table 73.3). Hymenal and posterior vestibule fissures and herpes simplex viral infection must be excluded. Fungal culture should be obtained to eliminate *Candida* infection, and digital examination of the vagina is performed to exclude vaginismus. Sometimes these disorders can coexist.

Downloaded for Anonymous User (n/a) at Egyptian Knowledge Bank from ClinicalKey.com by Elsevier on March 10, 2024. For personal use only. No other uses without permission. Copyright ©2024. Elsevier Inc. All rights reserved.

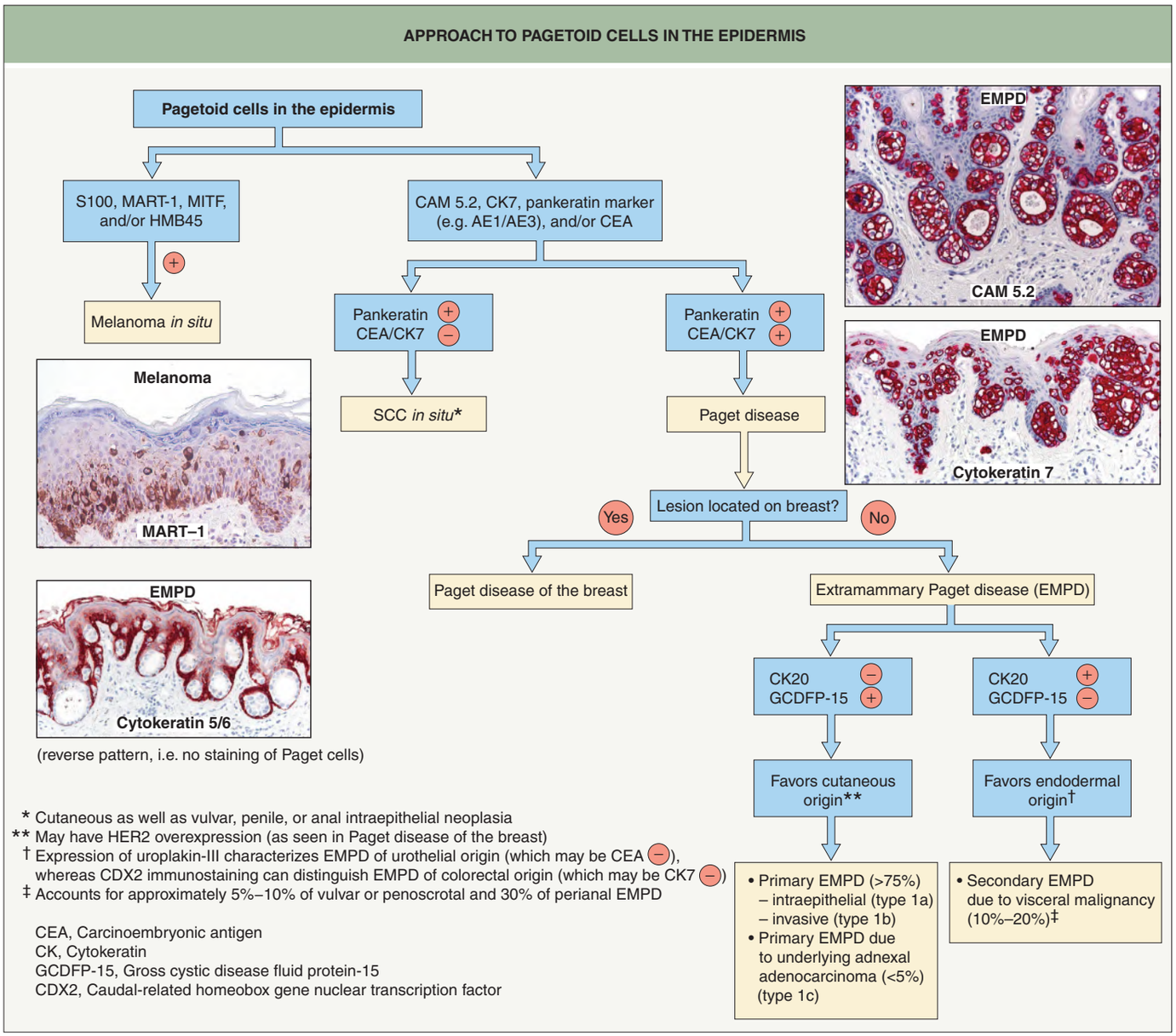

Fig. 73.16 Algorithm for the approach to pagetoid cells in the epidermis. The CAM 5.2 immunohistochemical stain is positive in >95% of Paget disease (mammary and extramammary) and approximately one-third of Bowen disease; it stains low-molecular-weight keratins. AE1 stains most subfamily A keratins (but not 12, 17, and 18) while AE3 stains subfamily B keratins. The differential diagnosis also includes pagetoid dyskeratosis (e.g. of the hand), Zuska disease, and clear cell papulosis.

Treatment

Topical local anesthetic agents (e.g. 5% lidocaine) applied before intercourse may be beneficial. Pelvic floor exercises, vaginal dilator training, and pelvic floor electromyography with biofeedback may prove useful. For a small number of women, surgery (e.g. modified vestibulectomy) might be helpful, but the role of surgery remains controversial[41].

Generalized Vulvodynia/Scrotodynia (Dysesthetic Vulvodynia/Scrotodynia)

Key features

- Burning and/or pain
- Clinical examination of vulva or scrotum is normal

Introduction

Persistent burning pain is characteristic and patients have often consulted many doctors before the correct diagnosis is made. Depression may be a feature of any chronic pain syndrome.

Scrotodynia is probably analogous to vulvodynia; however, there is less published on the subject[42]. Precipitating events include sexual activity, exercise, friction, and heat. Pain may also affect the penis.

Clinical features

Pain, often accompanied by a burning sensation, is felt over the entire vulva, scrotum, or penis, and it may extend down the thighs. The genital area may hurt even when nothing is touching it. Often, symptoms are worse on sitting or walking up stairs. Wearing of underwear may be impossible. On inspection, the scrotum or vulva looks entirely normal.

Differential diagnosis

Other causes of genital pain, e.g. infection (bacterial, viral, or fungal), lichen sclerosus, or lichen planus, must be excluded by examination before the diagnosis can be made. A potassium hydroxide (KOH) preparation and/or fungal culture to exclude candidiasis is essential. It is important to test for dermographism, as treatment with antihistamines may greatly benefit these patients.

Treatment

Treatment strategies are very similar to those for localized vulvodynia or scrotodynia (see above)[40]. Treatment with pain-modifying medications,

Downloaded for Anonymous User (n/a) at Egyptian Knowledge Bank from ClinicalKey.com by Elsevier on March 10, 2024. For personal use only. No other uses without permission. Copyright ©2024. Elsevier Inc. All rights reserved.

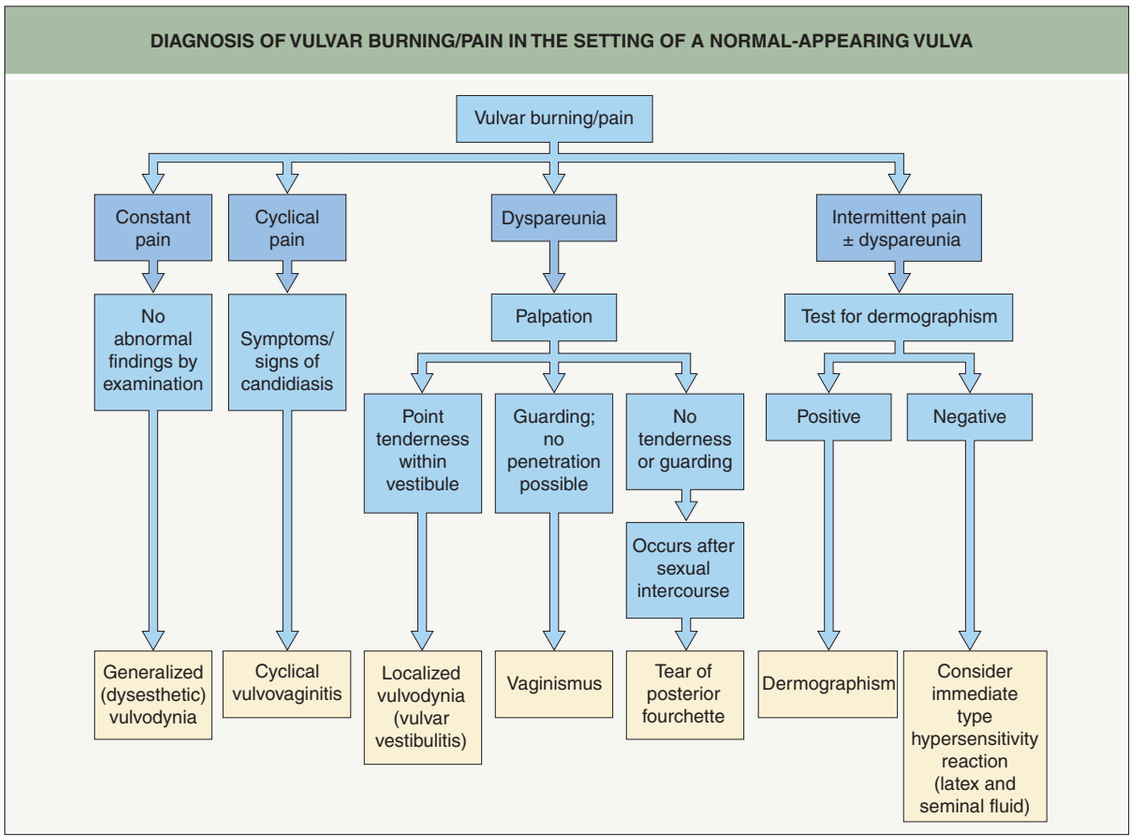

Fig. 73.17 Diagnosis of vulvar burning/pain in the setting of a normal-appearing vulva.

ISSVD TERMINOLOGY AND CLASSIFICATION OF PERSISTENT VULVAR PAIN
Vulvar pain caused by a specific disorder*
• Infectious (e.g. candidiasis, HSV infection) • Inflammatory (e.g. lichen planus, lichen sclerosus, immunobullous disorders) • Neoplastic (e.g. Paget disease, squamous cell carcinoma) • Neurologic (e.g. post-herpetic neuralgia, spinal nerve compression, neuroma) • Iatrogenic (e.g. postoperative, post-chemotherapy, post-radiation) • Trauma (e.g. cutting, obstetrical) • Hormonal deficiencies (e.g. genitourinary syndrome of menopause [vulvovaginal atrophy], lactational amenorrhea)
Vulvodynia†
Descriptors
• Localized (e.g. vestibulodynia, clitorodynia, hemivulvodynia) *or* generalized *or* mixed (localized and generalized) • Provoked (e.g. insertional, contact) *or* spontaneous *or* mixed (provoked and spontaneous) • Onset (primary or secondary) • Temporal pattern (intermittent, persistent, constant, immediate, delayed)
*Women may have both a specific disorder (e.g. lichen sclerosus) and vulvodynia. †Vulvar pain of more than 3 months' duration without clear identifiable cause; may have potential associated factors.

Table 73.3 International Society for the Study of Vulvovaginal Disease (ISSVD) terminology and classification of persistent vulvar pain (2015).

e.g. amitriptyline, gabapentin, is most likely to be beneficial in this disorder. Despite a variety of treatments, there remains a group that fails to respond.

Anal Pain

Anal pain may occur in both men and women and it shares many features with vulvodynia and scrotodynia. Associated depression is frequent.

BENIGN LESIONS OF THE GENITALIA	
Common	
• Angiokeratomas • Bartholin cysts • Epidermoid cysts, milia • Fordyce spots • Melanocytic nevi	• Mucosal melanosis • Pearly penile papules • Urethral caruncle • Vestibular papillomatosis
Less common	
• Endometriosis • Fox–Fordyce disease • Hidradenoma papilliferum • Idiopathic calcinosis of the scrotum	• Papular acantholytic dyskeratosis* • Perineal pyramidal protrusion • Steatocystomas • Syringomas
*Somatic mutations in *ATP2A2* and *ATP2C1* detected.	

Table 73.4 Benign lesions of the genitalia. Papules can also be due to infections, e.g. mollusca contagiosa and condylomata acuminata. If a firm penile lesion is linear, consider sclerosing lymphangitis.

BENIGN LESIONS

A wide variety of benign lesions can be found in the anogenital area (Table 73.4). Some of the more important lesions are discussed below.

Epidermoid Cysts

Epidermoid cysts are frequently encountered on the glabrous labia majora and scrotum, and may be multiple. They are yellow, vary in size, and may become inflamed. Treatment is by excision, but this is only necessary if the cyst is symptomatic.

Vestibular Papillomatosis

Papillomas within the vestibule are found in ~45% of premenopausal women and 10% of postmenopausal women. They are pink, asymptomatic, fine projections. Women should be reassured that the finding is normal.

Downloaded for Anonymous User (n/a) at Egyptian Knowledge Bank from ClinicalKey.com by Elsevier on March 10, 2024. For personal use only. No other uses without permission. Copyright ©2024. Elsevier Inc. All rights reserved.

SYSTEMIC DISEASES THAT MAY PRESENT IN THE ANOGENITAL REGION	
Systemic disease	**Clinical findings in the anogenital region**
Behçet disease	Recurrent aphthous ulcers (see text and Ch. 26)
Crohn disease	Recurrent abscesses, sinuses, and fistulas; linear (knife-cut) fissures; firm swelling of the labia or scrotum; firm anal "skin tags" (see Ch. 93)
Graft-versus-host disease	Fissures, erosions, ulcerations Can resemble anogenital lichen sclerosus or lichen planus Men: balanitis, phimosis Women: labial fusion, vaginal scarring with stenosis
Langerhans cell histiocytosis	Multiple red–brown papules and nodules, extending to thighs (usually children) Intertrigo-like erythema of the inguinal creases that may become erosive (see Ch. 91)
Neutrophilic dermatoses (e.g. Sweet syndrome)	Red to purple papules and nodules in association with fever
Zinc deficiency • Inherited • Acquired	Periorificial erythema, erosions, and crusting (see Ch. 51) Superimposed candidal infections

Table 73.5 Systemic diseases that may present in the anogenital region.

THE ANOGENITAL REGION AND SYSTEMIC DISEASE

There are a number of systemic disorders that may initially present in the anogenital region (Table 73.5). For example, Behçet disease is a rare multisystem inflammatory disorder in which recurrent oral aphthae are often accompanied by genital erosions or ulcers, in addition to arthritis, uveitis, neurologic disorders such as cranial nerve palsies and mono- and hemiparesis, arterial and venous thromboses, and pathergy (see Ch. 26). The disease is more prevalent in individuals from the Mediterranean basin, Japan, and Korea; it typically presents in young adults in their third or fourth decade of life. Recurrent flares and remissions are to be expected. Treatment options are outlined in Table 26.15.

INFECTIONS

Sexually transmitted infections (see Chs. 78 & 82) and condylomata acuminata (see Ch. 79) are described elsewhere, but miscellaneous infections that favor the anogenital region are discussed below.

Perianal Streptococcal Disease

The typical presentation is that of a 3- or 4-year-old boy with erythema and sometimes crusting of the perianal area[43] (see Ch. 74). Constipation is frequent because of discomfort. Similar findings may extend from the vaginal introitus onto the vulva in girls and less often around the urethral meatus in boys. The disease can be associated with guttate psoriasis and is frequently misdiagnosed as irritant dermatitis or candidiasis. Specimens for bacterial culture must be obtained. Group A β-hemolytic streptococci are responsible. Treatment is with oral penicillin, amoxicillin, or a first-generation cephalosporin.

Recurrent Toxin-Mediated Perineal Erythema

Recurrent toxin-mediated perineal erythema is an unusual condition that presents 2–3 days after a throat infection as a fine diffuse macular erythema of the perineal region[44]. Marked local edema may be present and the hands may be similarly affected. Desquamation follows the erythema and the condition can be recurrent. Streptococcal or staphylococcal pharyngitis is the most common cause and the erythema is toxin-mediated. Long-term prophylactic penicillin may be beneficial in some patients.

Kawasaki Disease

Kawasaki disease may be triggered by bacterial toxins or viral antigens, but the exact cause has not been elucidated. It is a disease of children. In up to two-thirds of cases, perineal erythema may be a presenting feature (see Ch. 81); additional findings include strawberry tongue, fissured lips, fever, and lymphadenopathy, followed by desquamation of the hands and feet. Coronary artery aneurysms may be life-threatening. Treatment is with aspirin and IVIg. Perineal erythema has also been observed in multisystem inflammatory syndrome in children (MIS-C) due to SARS-CoV-2 infection.

Fournier Gangrene

Fournier gangrene is a severe necrotizing infection of the external genitalia, perineum, or perianal area that occurs in patients with an underlying predisposition such as diabetes or immunosuppression[45] or who are receiving SGLT2 inhibitors. The infection is polymicrobial. Extensive surgical debridement with prolonged systemic antibiotics is necessary.

Erythrasma

Erythrasma is characterized by pigmented patches or thin plaques with fine scale that tend to occur in flexural areas, including the groin. Coral pink fluorescence under Wood's lamp examination is diagnostic. Distinction from dermatophytosis is usually possible clinically, as scaling is diffuse in erythrasma and there is no tendency toward central clearing.

Dermatophytosis

Chronic, slowly advancing, scaly erythematous lesions may be seen in the groin (tinea cruris) or the medial buttocks in addition to the upper thighs. Central clearing is often present and pustules may be seen; there is usually (if not always) concomitant tinea pedis and/or unguium. The diagnosis is made by microscopy and culture of skin scrapings.

Genital Candidiasis

Key features

- *Candida* spp. are normal commensals
- *Candida albicans* is responsible for 80%–90% of infections
- Underlying factors must be sought, e.g. diabetes, corticosteroids, systemic antibiotics
- In female patients usually seen during the reproductive years; occurs in infants but is uncommon in children or after menopause unless a risk factor is present

Introduction

It is important to confirm the infection by microscopy (KOH preparation) and culture because many genital skin problems in men and women are erroneously attributed to candidiasis.

Epidemiology

Candida spp. are normal commensals of the mucosal surfaces of the gastrointestinal and female genital tracts and may be found in small numbers in moist areas of skin[46]. There are at least 20 *Candida* spp. that can cause infections but evidence regarding their pathogenicity is conflicting. Resistance to imidazoles is an emerging problem.

Etiology

Candidiasis is more commonly seen in diabetics, especially when glycemic control is poor, and the immunosuppressed, as well as during treatment with systemic corticosteroids or broad-spectrum antibiotics. Candidiasis can be sexually transmitted and this is probably most important in recurrent infections. Polymorphisms in the mannose-binding lectin 2 gene (*MBL2*) have been implicated in some cases of severe recurrent candidiasis[47].

Downloaded for Anonymous User (n/a) at Egyptian Knowledge Bank from ClinicalKey.com by Elsevier on March 10, 2024. For personal use only. No other uses without permission. Copyright ©2024. Elsevier Inc. All rights reserved.

Clinical features

In men, balanitis, balanoposthitis, or rarely, widespread involvement of the perianal area, perineum, and groin is seen (see Ch. 77). Balanitis is more common in the uncircumcised man. The skin is erythematous and glazed with yellow pustules and erosions. In severe infections, edema may prevent retraction of the foreskin.

Women with candidiasis complain of pruritus and non-offensive vaginal discharge. Creamy white curds are visible on the vaginal walls, and there is vulvar erythema and sometimes fissuring. In severe cases swelling and pustules may be seen.

In both sexes, candidiasis may affect the perianal area with sheet-like erythema and fissuring. The inguinal–scrotal fold in men is a frequent site of involvement, and here, in addition to the erythema, the skin focally may appear white due to maceration of the accompanying scale. Satellite lesions, including pustules, are often seen.

In babies, candidiasis is a common cause of diaper dermatitis. There may be rapid spread of erythema and pustules that typically affect the skin creases, unlike the more common irritant dermatitis. Rarely, a nodular ulcerated variant may occur.

Differential diagnosis

Many inflammatory conditions of the genitalia are treated initially as a "yeast" infection. The presence of pseudohyphae alone is not sufficient to make the diagnosis; the appropriate clinical signs must also be present. Subcorneal pustules and erosions are also seen in impetigo, but this is excluded by a bacterial culture. In women, other causes of a vaginal discharge, including bacterial vaginosis, *Trichomonas* infection and desquamative inflammatory vaginitis, need to be considered. Some cases are mistakenly diagnosed as vulvar eczema.

Treatment

Topical polyene or imidazole antifungals may suffice in localized balanitis or intertrigo (see Ch. 127). The addition of a mild topical corticosteroid may help ameliorate symptoms. For vulvovaginal candidiasis, intravaginal imidazoles and single-dose oral fluconazole 150 mg are equally effective; in severe acute infections or in complicated infections (e.g. associated diabetes, immunocompromised state), these therapies should be repeated after 3 days. For non-*C. albicans* infections, nystatin pessaries or boric acid suppositories are recommended. Sexual partners only need treatment if they are symptomatic. An essential intervention is rectifying underlying causes such as uncontrolled diabetes.

Recurrent Candidiasis

Recurrent candidiasis is defined as more than four episodes of candidiasis per year. Precipitating factors must be identified, including hormone replacement therapy. Advice should be given on foreskin hygiene and keeping the perineal area cool with cotton underwear. In women, premenstrual exacerbations are typical. Possible regimens include oral fluconazole 150 mg weekly for 6 months or clotrimazole 500 mg vaginal tablet weekly for 6 months.

Schistosomiasis

Granulomatous lesions of the genitalia are primarily a manifestation of *Schistosoma haematobium* infection. Men may present with epididymitis, dysuria, or prostatitis and women with dyspareunia, dysmenorrhea, or contact bleeding.

EROSIVE GENITAL DISEASE

Erosions and ulcerations are seen in a wide variety of conditions (Table 73.6). Genital aphthae and HSV infections are common. Erosions may occur after scratching or rubbing or as a result of blister formation. To determine the cause of the erosions, it is essential to take a careful history and perform a full examination of the skin, including other mucosal surfaces. For example, a white lacy pattern on the buccal mucosa may suggest a diagnosis of lichen planus. Further investigations will be determined by the clinical appearance, but swabs for bacterial and fungal culture are often necessary. Biopsies of lesional skin for light microscopy and perilesional skin for direct immunofluorescence are indicated if an autoimmune blistering disorder is suspected.

CAUSES OF GENITAL EROSIONS AND ULCERATIONS
Lichen sclerosus
Erosive lichen planus
Genital aphthae/aphthosis*
Infection • Candidiasis • Herpes simplex or herpes zoster • Impetigo (*Staphylococcus*/*Streptococcus*) • Primary syphilis, chancroid • Epstein–Barr virus (EBV)†,‡, cytomegalovirus†, *Mycoplasma pneumoniae*†,¶ • Tuberculosis
Intraepithelial neoplasia
Squamous cell carcinoma and other malignancies
Trauma
Zoon balanitis/vulvitis
Acquired bullous diseases (see Table 73.7)
Drug reactions • Fixed drug eruption • Stevens–Johnson syndrome • Toxic erythema of chemotherapy • Other (e.g. penile/foscarnet, scrotal/multi-kinase inhibitors)
Inherited bullous diseases • Hailey–Hailey disease • Epidermolysis bullosa
Complex aphthosis – Behçet disease, inflammatory bowel disease
Crohn disease
Extramammary Paget disease
Langerhans cell histiocytosis
Pyoderma gangrenosum
Necrolytic migratory erythema, acrodermatitis enteropathica
Papular acantholytic dyskeratosis§

*Includes reactive non-sexually related acute genital ulcers which can be triggered by a variety of viral and bacterial infections.
†Cause/trigger of reactive non-sexually related acute genital ulcers.
‡Primary EBV infection diagnosed via EBV IgM antibodies or PCR.
¶Trigger for *Mycoplasma*-induced rash and mucositis (MIRM)/reactive infectious mucocutaneous eruption (RIME).
§Papules more common than erosions; it can occur in the setting of Hailey–Hailey disease or be associated with a somatic mutation in *ATP2C1* or *ATP2A2*.

Table 73.6 Causes of genital erosions and ulcerations. Infection-related disorders include erythema multiforme major, *Mycoplasma*-induced rash and mucositis (MIRM), and reactive non-sexually related acute genital ulcers.

Primarily in adolescent girls, reactive non-sexually related acute genital ulcers, sometimes referred to as Lipschutz ulcers, may be seen (Fig. 73.18). These ulcers can be large and deep and are triggered by a variety of viral or bacterial infections, including Epstein–Barr virus, *Mycoplasma*, cytomegalovirus, influenza, and streptococci. However, a cause is not always identified.

Acquired Autoimmune Bullous Diseases

Immunofluorescence (direct and indirect) is an essential investigation in suspected autoimmune bullous diseases as it may be very difficult to distinguish between the different blistering disorders on clinical grounds alone (Table 73.7)[48]. The most common autoimmune bullous diseases seen in the genital region are bullous pemphigoid, including the childhood variant[49], and mucous membrane pemphigoid. Unless blisters are seen or described, anogenital mucous membrane pemphigoid is often indistinguishable from erosive lichen planus; thus, histology and immunofluorescence are essential (Fig. 73.19). The extent and severity of the disease determine the treatment, which usually consists of a combination of topical and systemic anti-inflammatory and immunosuppressive agents. Great symptomatic relief can be gained from the use of potent topical corticosteroids, either as sole treatment in localized disease or as an adjunct to systemic treatment in widespread or more severe disease.

Downloaded for Anonymous User (n/a) at Egyptian Knowledge Bank from ClinicalKey.com by Elsevier on March 10, 2024. For personal use only. No other uses without permission. Copyright ©2024. Elsevier Inc. All rights reserved.

Fig. 73.18 Reactive non-sexually related acute genital ulcers associated with primary EBV infection. Extreme pain with urination required placement of a Foley catheter in this 13-year-old girl. EBV-related genital ulcers are often misdiagnosed as a genital herpes simplex viral infection. *Courtesy Julie V. Schaffer, MD.*

Fig. 73.19 Mucous membrane pemphigoid of the vulva. Ulcerations and scarring of the perianal area and perineum (positive direct immunofluorescence distinguished this from erosive lichen planus).

CLINICAL CHARACTERISTICS OF AUTOIMMUNE BULLOUS DISEASES THAT MAY PRESENT IN THE ANOGENITAL REGION			
Disease	**Age group**	**Clinical features**	**Chapter**
Bullous pemphigoid	Older adults; rare in children	Tense blisters that favor flexural sites, including the vulva in girls No scarring	Ch. 30
Mucous membrane (cicatricial) pemphigoid	Middle-aged and older adults	In the anogenital region, erosions and scarring but rarely blisters Involvement of oral and ocular mucosae	Ch. 30
Linear IgA bullous dermatosis	Children and adults	Trunk and limbs most common sites, but often face and genitalia in children Annular and polycyclic lesions composed of vesiculobullae	Ch. 31
Epidermolysis bullosa acquisita	Adults > children	Mechanobullous form with scarring more common than inflammatory form	Ch. 30
Pemphigus vulgaris	Peak age = 50–60 years	Initially mucosal involvement with primarily painful erosions Fragile cutaneous blisters and erosions may then develop	Ch. 29
Pemphigus vegetans	Peak age = 50–60 years	May have flexural accentuation, including inguinal	Ch. 29
Paraneoplastic pemphigus	Adults ≫ children	Erosive mucosal involvement that is severe & recalcitrant	Ch. 29

Table 73.7 Clinical characteristics of autoimmune bullous diseases that may present in the anogenital region.

Acquired Inflammatory Bullous Diseases

Erythema multiforme and Stevens–Johnson syndrome

Erythema multiforme (EM, primarily the major form) and Stevens–Johnson syndrome (SJS) may present as a bullous eruption in the genital region. In recurrent EM, HSV infection should be sought, remembering that there may be a delay of up to 2 weeks from infection to appearance of the lesions. In recurrent cases, a trial of prophylactic oral anti-HSV therapy may be indicated. Confluent dusky macular lesions point to SJS, in which drugs are the most common etiology. Prominent mucosal involvement also occurs in *Mycoplasma*-induced rash and mucositis (MIRM)/reactive infectious mucocutaneous eruption (RIME); see Ch. 20).

Fixed drug eruption

Recurrent erythematous or eroded plaques may occur on both skin and mucous membranes[50] (see Ch. 21). Often, cutaneous lesions are strikingly round, but this may not hold true in mucous membrane sites. The lesions recur in exactly the same site with each exposure to the drug. Bullous genital lesions frequently present as erosions. Common culprits are acetaminophen (paracetamol), tetracyclines, trimethoprim–sulfamethoxazole, and nonsteroidal anti-inflammatory drugs.

Inherited Bullous Disease

Hailey–Hailey disease

Patients with autosomal dominant Hailey–Hailey disease have recurrent involvement of flexural areas (see Ch. 59). Expanding erythematous plaques with superimposed erosions and sometimes vesicles and pustules are seen. In the inguinal creases, there is a particular tendency to form hypertrophic plaques. Secondary infection with bacteria, fungi, and HSV is a frequent problem and must be excluded in any exacerbation; for recurrent disease, suppressive therapy may be considered. Topical corticosteroids in combination with antifungal/antibacterial agents can ease symptoms. Low-dose naltrexone or CO_2 laser ablation may also prove helpful.

Additional figures and table on the 2015 International Society for the Study of Vulvovaginal Disease (ISSVD) terminology of vulvar squamous intraepithelial lesions, available in our eBook (see inside front cover for access code).

Downloaded for Anonymous User (n/a) at Egyptian Knowledge Bank from ClinicalKey.com by Elsevier on March 10, 2024. For personal use only. No other uses without permission. Copyright ©2024. Elsevier Inc. All rights reserved.

eFig. 73.1 Lichen sclerosus of the perianal region.

eFig. 73.3 Perianal lichen sclerosus. Well-demarcated ivory-white plaques with focal erosions and purpura. *Courtesy Julie V. Schaffer, MD*.

eFig. 73.2 Lichen sclerosus of the glans penis with extension onto the shaft. Note the hypopigmentation and purpura as well as scarring and ongoing inflammation. *Courtesy Kalman Watsky, MD*.

eFig. 73.4 Lichen planus of the penis. Multiple small, flat-topped, violaceous papules. *Courtesy Kalman Watsky, MD*.

Downloaded for Anonymous User (n/a) at Egyptian Knowledge Bank from ClinicalKey.com by Elsevier on March 10, 2024. For personal use only. No other uses without permission. Copyright ©2024. Elsevier Inc. All rights reserved.

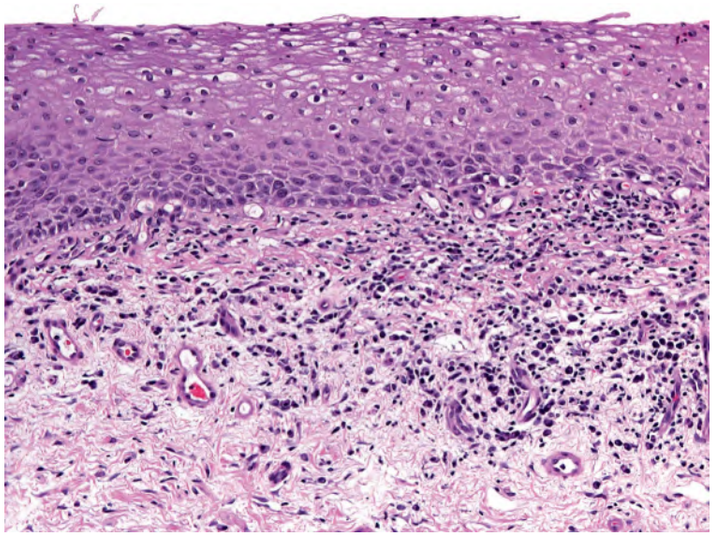

eFig. 73.5 Zoon balanitis – histopathologic features. Lichenoid infiltrate in the upper dermis with a predominance of plasma cells. Additional features include increased dermal vascularization. Of note, plasma cells are commonly seen in mucosal biopsies, irrespective of the disorder. *Courtesy Lorenzo Cerroni, MD.*

eFig. 73.6 Lichen simplex chronicus of the scrotum. Note the increased skin markings with sparing of the scrotal raphe. *Courtesy Department of Dermatology, Medical University of Graz.*

eFig. 73.7 Psoriasis involving the glans penis and distal finger. Thin pink plaques are seen with scale and erosions. *Courtesy Kalman Watsky, MD.*

eFig. 73.8 Extramammary Paget disease. Well-demarcated erythematous plaques of the labia majora and mons pubis. Erosions and white scale are also present. *Courtesy Kalman Watsky, MD.*

eFig. 73.9 Extranodal NK/T cell lymphoma, nasal type. Ulcerated indurated plaque involving the glans and distal shaft of the penis. *Courtesy Luis Requena, MD.*

Downloaded for Anonymous User (n/a) at Egyptian Knowledge Bank from ClinicalKey.com by Elsevier on March 10, 2024. For personal use only. No other uses without permission. Copyright ©2024. Elsevier Inc. All rights reserved.

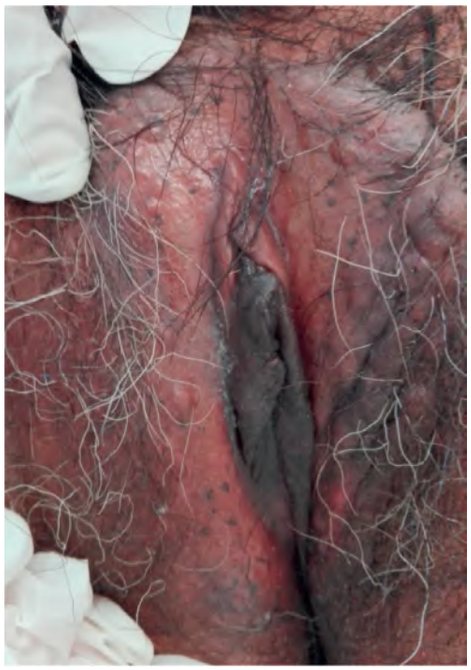

eFig. 73.10 Vulvar syringomas. Multiple skin-colored papules on the labia majora in addition to mucosal melanosis. *Courtesy Diana Carolina Palacios Narváez, MD, and María Elisa Vega Memije, MD.*

2015 INTERNATIONAL SOCIETY FOR THE STUDY OF VULVOVAGINAL DISEASE TERMINOLOGY OF VULVAR SQUAMOUS INTRAEPITHELIAL LESIONS		
Vulvar lesion	**Other names**	**Comments**
Low-grade squamous intraepithelial lesion (LSIL)	Vulvar LSIL Flat condyloma HPV effect VIN 1 (historically)	• Often associated with low-risk HPV subtypes (e.g. 6, 11) • Negligible risk for malignant transformation to SCC
High-grade squamous intraepithelial lesion (HSIL)	Vulvar HSIL Usual type VIN (uVIN) Undifferentiated VIN VIN 2,3 (historically)	• Associated with high-risk HPV subtypes (e.g. 16, 18, 31) • ~20% risk of developing SCC
Differentiated VIN (dVIN)	VIN simplex type (historically)	• Associated with vulvar dermatoses, e.g. lichen sclerosus • ~30% risk of developing SCC

eTable 73.1 2015 International Society for the Study of Vulvovaginal Disease (ISSVD) terminology of vulvar squamous intraepithelial lesions. HPV, human papillomavirus; SCC, squamous cell carcinoma; VIN, vulvar intraepithelial neoplasia.

Downloaded for Anonymous User (n/a) at Egyptian Knowledge Bank from ClinicalKey.com by Elsevier on March 10, 2024. For personal use only. No other uses without permission. Copyright ©2024. Elsevier Inc. All rights reserved.